



Visual attention deficits in Alzheimer's disease: an fMRI study

Jing Hao^a, Kuncheng Li^{a,*}, Ke Li^b, Dexuan Zhang^c, Wei Wang^a, Yanhui Yang^a, Bin Yan^b,
Baoci Shan^b, Xiaolin Zhou^c

^a Department of Radiology, Xuanwu Hospital, Capital University of Medical Sciences, No. 45 Changchun Street, Beijing 100053, PR China

^b Institute of High Energy Physics, Chinese Academy of Sciences, Beijing 100039, PR China

^c Department of Psychology, Peking University, Beijing 100034, PR China

Received 7 December 2004; received in revised form 25 April 2005; accepted 2 May 2005

Abstract

Cognitive and neuroscience studies indicate that attentional operations are impaired in Alzheimer's disease (AD). Our goal was to define the anatomical areas of activation associated with visual attention processing and to define deficits or changes that may occur in AD patients compared with control group. Thirteen AD patients and 13 age- and education-matched normal controls were tested in two visual search tasks (one was a conjunction task, where feature binding is required. The other was a subset task, where group stimuli is needed without feature binding) using fMRI techniques. After stereotactical normalization, voxel-by-voxel *t* statistics was used to compare activated brain areas between patients and control subjects. Our findings suggest that both search tasks are controlled by partially overlapping cerebral networks, including parietal, frontal and occipital–temporal cortical regions and primary visual cortex. The AD patient group showed less activation in both parietal lobes and the left frontal regions, while increased activation was found in the right frontal lobes and the right occipito-temporal cortical regions with the conjunction task. In the subset task, decreased activation in AD patients was seen in the left parietal lobe and bilateral frontal lobes, while increased activation was seen in both medial temporal lobes. In addition, for the comparison between tasks, The difference is very small for AD patients. Control group showed a higher amplitude in the right prefrontal region, temporal cortical regions and parietal lobe. These results indicate that attention deficits in AD patients may be attributed to both binding problem and grouping inefficiency. © 2005 Elsevier Ireland Ltd. All rights reserved.

Keywords: Functional MRI; Visual search; Attention; Alzheimer's disease

Alzheimer's disease (AD) is a neurodegenerative disease that is the major cause of dementia in older adults. In most cases, AD begins as a memory disorder. Recently, there has been a suggestion that memory deficit is followed by attentional difficulties [2,3,15,19], including both auditory [13] and visual [12] selective processing, visual search [8,22,26,27] and attention shifting [6]. However, attentional impairments have not been examined extensively and identification of the cerebral components and neural basis of attentional deficits is still in its infancy. The purpose of the present functional Magnetic Resonance Imaging (fMRI) study was to define the anatomical areas of activation associated with visual attention

processing and to define deficits or changes that may occur in a group of AD patients compared with control group.

Thirteen patients (mean age, 62.6 ± 7.8 ; eight females and five males) suffering from mild to moderate AD (diagnosed according to NINCDS-ADRDA [19] and ICD-10 criteria [1]) were recruited from our outpatient memory disorder unit. The severity of cognitive impairment was assessed using the Mini Mental State Examination (MMSE) [7] (group mean score, 18.3 ± 4.2). A group of 13 normal subjects (7 females and 6 males) matched for age (mean age 64.5 ± 6.7) and education was recruited from the community. Controls had a mean score of 27.8 ± 2.6 points in the MMSE and no pathological changes on screening T₁ and T₂ structural cranial MR images. Subjects and patients with color blindness were excluded from this study. All subjects signed a written informed consent according to the Declaration of Helsinki (BMJ 1991;

* Corresponding author. Tel.: +86 10 63013355 2376;
fax: +86 10 63013355 2376.

E-mail address: nancyhaojing@hotmail.com (K. Li).

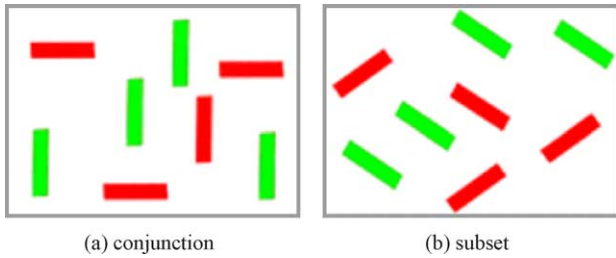


Fig. 1. Diagrammatic representation of the visual search tasks used in the study.

302; 1194) and the experiment protocol was approved by the local research ethics committee.

Each participant completed two types of visual search tasks. One was a conjunction task, where the target was a vertical red bar and the distracters were green vertical and red horizontal bars (Fig. 1a), i.e., two feature classes (e.g. color and orientation) are present in the array and spatial attention and feature binding are required. The other was a subset task, where again two features are present but only one of them is needed in order to group stimuli together (the subset) to allow parallel processing without the need for feature binding [9]. In which the target was a red bar of a particular orientation, among green distracters of the same orientation and red distracters of a different orientation (Fig. 1b). The orientations ($0\text{--}90^\circ$ in 10 steps) of the bars changed randomly from trial to trial with a minimum difference of 30° between the two orientations present on any trial. The target was therefore the red bar with the odd-one-out orientation. The visual display subtended a maximum size of 12° horizontally and 8° vertically. Three stimulus set sizes (i.e., the number of bars in

Table 2
Anatomical regions activated during the conjunction task ($P > 0.001$)

Age-matched controls					AD patients				
Region (Brodmann area)	Voxels	X	Y	Z	Region (Brodmann area)	Voxels	X	Y	Z
L-precuneus (BA18)	27717	-26	-68	44	L-superior parietal lobule (BA7)	13813	-36	-42	62
L-superior parietal lobule (BA7)	27717	-32	-56	50	L-inferior occipital gyrus (BA18)	13813	-20	-104	0
L-postcentral gyrus	27717	-50	-32	50	R-superior parietal lobule (BA7)	5280	32	-66	50
R-superior parietal lobule (BA7)	8070	32	-60	48	R-medial occipital gyrus (BA19)	5280	34	-94	6
R-frontal eye fields (BA6)	4030	32	-6	64	R-inferior parietal lobule (BA40)	5280	38	-48	44
R-inferior frontal gyrus (BA47)	4030	56	16	2	R-medial frontal gyrus (BA 10)	1090	44	50	-4
L-basal ganglia	1444	-16	-14	14	L-medial frontal gyrus (BA 46)	476	-48	42	20
R-basal ganglia	1444	18	0	18	L-medial frontal gyrus (BA10)	476	-36	60	12
R-thalamus	1444	14	-6	12	R-inferior temporal gyrus (BA37)	213	44	-64	-14
R-medial frontal gyrus (BA 10)	279	42	56	8	R-inferior frontal gyrus (BA45)	114	30	26	2
R-inferior frontal gyrus (BA46)	279	50	46	14					

Tables 2 and 3 and Fig. 2a–d), including parietal, frontal, occipital–temporal cortical regions and primary visual cortex, as well as several subcortical structures.

The AD patient group showed less activation in both parietal lobes and the left frontal region, while increased activation was found in the right frontal lobe and the right occipito-temporal cortex (OTC) with the conjunction task (Fig. 2e). With the subset task, less activation in AD patients was revealed in the left parietal lobe and both frontal lobes, while more activation was present in the right medial temporal lobe (Fig. 2f).

An image map showing the difference of activations was derived by subtracting the subset task from the conjunction task. The normal controls showed a higher amplitude in the right prefrontal lobe, both temporal cortical regions and parietal lobes (Fig. 3). The difference between tasks is very small for AD patients, including bilateral parietal lobes, the left occipital–temporal cortical region and the left primary visual cortex (Fig. 4).

Here we examine the difference between visual search, in a conjunction search, two types of distracters are used, each type sharing one feature in common with the target stimulus. As spatial attention is important in conjunction tasks [30,31], the more distracters there are in the array, the longer the

viewer takes to find the target or indicate its absence. This is known as serial search, since each stimulus or small clusters of them must be processed in turn until the target is either found or excluded. Subset search has been suggested as one way of allowing the selection of a particular feature (e.g. color) to be processed in parallel, without interference from other features (e.g. orientation). In this task, there are again two types of distracters (e.g. orientation and color) but only one feature has constant and known invariables (e.g. color always red). The second feature varies from trial to trial (e.g. the distracter/target orientation changes). The task is therefore to search through the array for the sole red target with a particular orientation among green distracters of the same orientation and red distracters of a different orientation [9].

In the present experiment, we recorded differential cortical activation during a conjunction search task and a subset search task and compared activations between tasks in both groups. Consistent overlap of cortical activity during conjunction search and subset search was found in the parietal, frontal and occipital–temporal cortical regions, primary visual cortex and several subcortical structures, including FEF (frontal eye field) and anterior and posterior IPS (intraparietal sulcus) [4,5]. In addition, each search task may involve specific mechanisms since the different search

Table 3
Anatomical regions activated during the subset task ($P > 0.001$)

Age-matched controls					AD patients				
Region (Brodmann area)	Voxels	X	Y	Z	Region (Brodmann area)	Voxels	X	Y	Z
R-cuneus (BA18)	25312	32	-92	4	R-superior parietal lobule (BA7)	14313	30	-68	56
R-medial frontal gyrus (BA9)	25312	52	14	42	R-superior parietal lobule (BA7)	14313	12	-66	60
R-superior parietal lobule (BA7)	25312	28	-56	50	R-medial occipital gyrus (BA19)	14313	56	-60	-14
L-medial occipital gyrus (BA19)	638	-52	-66	-10	R-superior frontal gyrus (BA 6)	1267	34	4	60
L-inferior occipital gyrus (BA19)	638	-44	-78	-4	R-inferior frontal gyrus (BA44)	1267	46	8	28
L-medial occipital gyrus (BA18)	638	-36	-58	-16	R-medial frontal gyrus (BA9)	1267	56	14	34
L-thalamus	556	-18	-18	16	L-medial occipita	1149	-52	-68	-60
R-basal ganglia	556	-14	-26	-4	L-inferior temporal gyrus (BA37)	1149	-60	-52	-14
L-thalamus	556	-12	-16	6	L-medial frontal gyrus (BA 46)	225	-46	34	24
L-inferior frontal gyrus (BA45)	272	-32	22	2	R-medial frontal gyrus (BA 46)	216	50	38	26
L-inferior frontal gyrus (BA45)	272	-40	14	6	R-cingulate cortex (BA 32)	216	4	22	38
L-medial temporal lobe (BA28)	272	28	-20	-6	R-frontal eye fields (BA6)	216	8	14	44

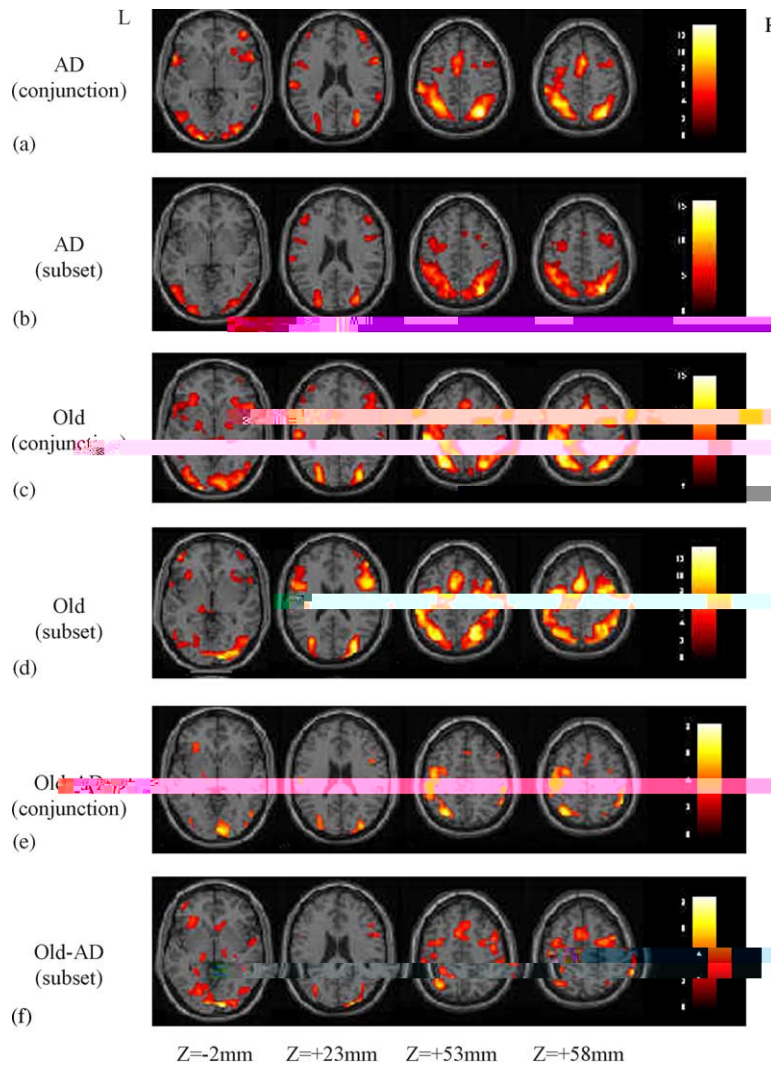


Fig. 2. Averaged brain activation involved in the different conditions (conjunction and subset task) of the two groups (AD patients and controls) (a–d) and the comparison between groups for the different conditions (e and f). Note: R designates the right hemisphere and L designates the left hemisphere.

tasks produce different magnitudes of activation in some brain areas of the network, right prefrontal cortex and FEF responded at a higher amplitude during the subset search and the left IPS responded at a higher amplitude during the conjunction search. In keeping with the results of previous lesion and functional imaging [2,4,5,15,25], the observed activations during conjunction and subset search most likely reflect covert selective attention. The differential fMRI responses of posterior parietal areas and the FEF should not be contaminated by sensory activation of parietal and FEF neurons. Saccadic eye movements are also unlikely to account for the recorded differential activations [5,26].

This experiment was concerned with the ability of AD patients to perform two types of what, for healthy people, would be efficient visual search tasks. We found that the AD patients searched significantly more slowly and made more errors compared with the controls on both tasks. In our previous study [14], we also found that less resource-demanding capabilities, tapped by the simple feature search, remained

relatively preserved in AD. Therefore, the result may arise because there is some damage to general attentional mechanisms in AD, and thus any attention-related task is affected. We found that with the conjunction task less activation in AD patients was demonstrated in the bilateral parietal lobes and the left frontal region, while increased activation was found in the right frontal lobe and the right occipito-temporal cortical region. In the subset task, less activation in AD patients was revealed in the left parietal lobe and bilateral frontal lobes, while increased activation was present in the right medial temporal lobe.

Given that parietal lobe dysfunction is a known pathological characteristic of AD, of particular interest in this study was the involvement of the posterior parietal cortex, which has an established role in orienting spatial attention [18,21,23] and which is critically involved in visual search [4,5,18]. Therefore, this may suggest that there are impairments in some cognitive processes associated with spatial attention in AD patients. Several interpretations about the nature of pari-

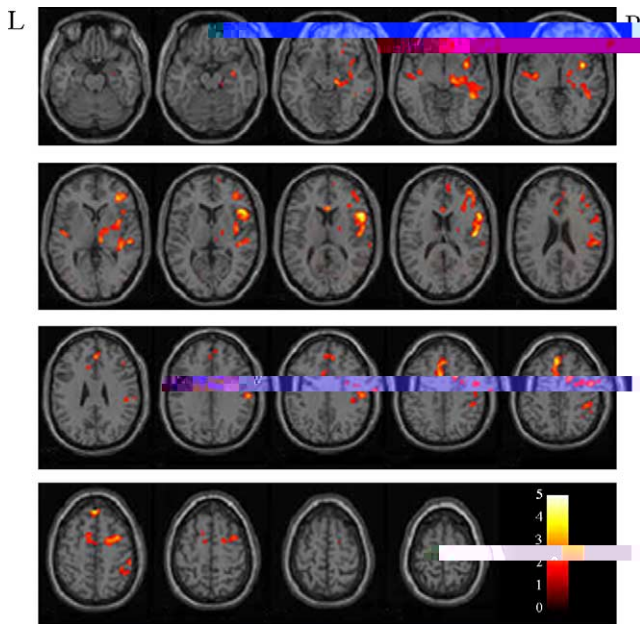


Fig. 3. Cortical activation for the conjunction task compared to the subset task in the controls. Note: R designates the right hemisphere and L designates the left hemisphere.

etal involvement during visual search are possible. Firstly, the parietal cortex could be involved in directing attention serially toward successive locations for the purpose of integrating the constituent features of individual items. In this interpretation, parietal activation reflects both spatial attention and feature binding mechanisms [27,29]. Secondly, the right parietal cortex is not responsible for both selective atten-

tion and feature binding, but rather is involved in selecting spatial locations which contained a particular feature variable (such as the color red). When target items can be segmented from neighboring distracters via similarity grouping, detection may not rely on spatial integration. These effects of distracter similarity are reflective of the role of perceptual grouping in visual search and constitute new evidence that it is not the mere search for conjunction targets that activates the superior, posterior parietal lobe [16,32]. Rather, it is the failure of grouping mechanisms to preattentively segment target from distracter items and the subsequent need for feature binding that engages superior parietal cortex. In the absence of these grouping relations, search isseriorget fe0843D ([27,293 0 0 0 scn 2.91Fir6TD ([16,.0 0 .839 1232 TD [(f)10 tionf atesfTJxvolvedv.65conjcting

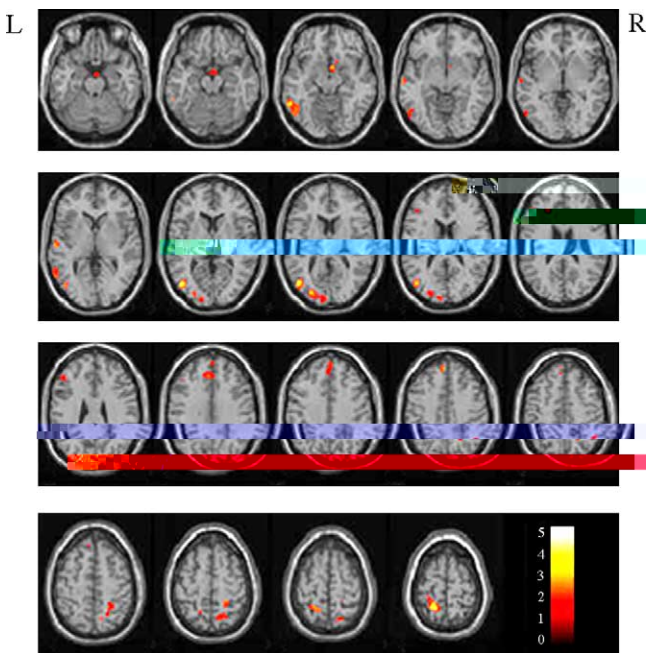


Fig. 4. Cortical activation for the conjunction task compared to the subset task in AD patients. Note: R designates the right hemisphere and L designates the left hemisphere.

increased activation of cortical regions subserving task processing or to the additional activation of regions initially not involved in the task [25,26].

In summary, the current study demonstrates that AD patients have a particular impairment in the conjunction and subset search tasks. There is less activation mainly located in the parietal cortex, with anterior cingulate cortex and frontal lobe dysfunction. This finding is consistent with previous experimental studies [8,27]. Based on the present results together with previous cognitive evidence, we suggest attention deficits in AD patients may be attributed to both binding problem and grouping inefficiency. Our results also agree with the idea that visual search information of AD patients provides an important source for unraveling the pathophysiological processes of this neurodegenerative disease.

Acknowledgements

We are grateful to two anonymous reviewers and to Professor Ken Maravilla (University of Washington School of Medicine) for helpful comments on the manuscript.

References

- [1] G.R. Bramer, International statistical classification of diseases and related health problems, tenth revision, World Health Stat. Q. 41 (1996) 32–36.
- [2] M. Corbetta, G.L. Shulman, F.M. Miezin, S.E. Petersen, Superior parietal cortex activation during spatial attention shifts and visual feature conjunction, *Science* 270 (1995) 802–805.
- [3] A. Cronin-Golomb, S. Corkin, F. Rizzo, J. Cohen, J.H. Growdon, K.S. Banks, Visual dysfunction in Alzheimer's disease: relation to normal aging, *Ann. Neurol.* 29 (1991) 41–52.
- [4] T.H. Donner, A. Kettermann, E. Diesch, F. Ostendorf, A. Villringer, S.A. Brandt, Involvement of the human frontal eye field and multiple parietal areas in covert visual selection during conjunction search, *Eur. J. Neurosci.* 12 (2000) 3407–3414.
- [5] T.H. Donner, A. Kettermann, E. Diesch, F. Ostendorf, A. Villringer, S.A. Brandt, Visual feature and conjunction searches of equal difficulty engage only partially overlapping frontoparietal networks, *NeuroImage* 15 (2002) 16–25.
- [6] J.V. Filoteo, D.C. Delis, P.J. Massman, T. Demadura, N. Butters, D.P. Salmon, Directed and divided attention in Alzheimer's disease: impairment in shifting of attention to global and local stimuli, *J. Clin. Exp. Neuropsychol.* 14 (1992) 871–883.
- [7] M.F. Folstein, S.E. Folstein, P.R. McHugh, Mini-mental state—a practical method for grading the cognitive state of patients for the clinician, *J. Psychiatr. Res.* 12 (1975) 189–198.
- [8] J.K. Foster, M. Behrmann, D.T. Stuss, Visual attention deficits in Alzheimer's disease: simple versus conjoined feature search, *Neuropsychology* 13 (1999) 223–245.
- [9] S. Friedman Hill, J.M. Wolfe, Second-order parallel processing: visual search for the odd item in a subset, *J. Exp. Psychol.: Hum. Percept. Perform.* 21 (1995) 531–551.
- [10] K.J. Friston, C.D. Frith, P.F. Liddle, R.S. Frackowiak, Comparing functional (PET) images: The assessment of significant change, *J. Cereb. Blood Flow Metab.* 11 (1991) 690–699.
- [11] K.J. Friston, A.P. Holmes, J.B. Poline, P.J. Grasby, S.C. Williams, R.S. Frackowiak, R. Turner, Analysis of fMRI time-series revisited, *NeuroImage* 2 (1995) 45–53.
- [12] L. Grande, R. McGlinchey-Berroth, W.P. Milberg, M.D. Esposito, Facilitation of unattended semantic information in Alzheimer's disease: evidence from a selective attention task, *Neuropsychology* 10 (1996) 475–484.
- [13] M. Gearing, R.E. Graves, E. Mohr, Breakdown of selective attentional mechanisms in Alzheimer's disease, *J. Clin. Exp. Neuropsychol.* 13 (1991) 69.
- [14] J. Hao, K.C. Li, K. Li, D.X. Zhang, W. Wang, B. Yan, Y.H. Yang, Y. Wang, Q. Chen, B.C. Shan, X.L. Zhou, Visual search in Alzheimer's disease—a fMRI study, *MIAR, LNCS* 3150 (2004) 204–212.
- [15] J.V. Haxby, C.L. Grady, E. Koss, B. Horwitz, L.L. Heston, M.B. Schapiro, R.P. Friedland, S.I. Rapoport, Longitudinal study of cerebral metabolic asymmetries and associated neuropsychological patterns in early dementia of the Alzheimer type, *Arch. Neurol.* 47 (1990) 753–760.
- [16] J. Hedg e, D.J. Felleman, The pop-out in some conjunction searches is due to perceptual grouping, *NeuroReport* 10 (1999) 143–148.
- [17] D.D. Kurylo, S. Corkin, J.F. Rizzo, Greater relative impairment of object recognition than of visuospatial abilities in Alzheimer's disease, *Neuropsychology* 10 (1996) 74–81.
- [18] U. Leonards, S. Sunaert, P. Van Hecke, G.A. Orban, Attention mechanisms in visual search—an fMRI study, *J. Cogn. Neurosci.* 12 (2000) 61–75.
- [19] G. McKhann, D. Drachman, M. Folstein, R. Katzman, D. Price, E.M. Stadlan, Clinical diagnosis of Alzheimer's disease: Report of the NINCDS-ADRDA Work Group under the auspices of Department of Health and Human Services Task Force on Alzheimer's disease, *Neurology* 34 (1984) 939–944.
- [20] M.J. Mentis, B. Horwitz, C.L. Grady, G.E. Alexander, J. VanMeter, J.M. Maisog, P. Pietrini, M.B. Schapiro, S.I. Rapoport, Visual cortical dysfunction in Alzheimer's disease evaluated with a temporally graded "stress test" during PET, *Am. J. Psychiatry* 153 (1996) 32–40.
- [21] M.M. Mesulam, Spatial attention and neglect: parietal, frontal and cingulate contributions to the mental representation and attentional targeting of salient extrapersonal events, *Phil. Trans. R. Soc. Lond. B Biol. Sci.* 354 (1999) 1325–1346.
- [22] R.D. Nebes, C.B. Brady, Focused and divided attention in Alzheimer's disease, *Cortex* 25 (1989) 305–315.
- [23] M.I. Posner, J. Driver, The neurobiology of selective attention, *Curr. Opin. Neurobiol.* 2 (1992) 165–169.
- [24] D. Prvulovic, D. Hubl, A.T. Sack, L. Melillo, K. Maurer, L. Frolich, H. Lanfermann, F.E. Zanella, R. Goebel, D.E.J. Linden, T. Dierks, Functional imaging of visuospatial processing in Alzheimer's disease, *NeuroImage* 17 (2002) 1403–1414.
- [25] M. Rizzo, S.W. Anderson, J. Dawson, M. Nawrot, Vision and cognition in Alzheimer's disease, *Neuropsychologia* 38 (2000) 1157–1169.
- [26] A. Rosler, A. Mapstone, A.K. Hays, M.M. Mesulam, A. Rademaker, D.R. Gitelman, S. Weintraub, Alterations of visual search strategy in Alzheimer's disease and aging, *Neuropsychology* 14 (2000) 398–408.
- [27] A. Tales, S.R. Butler, J. Fossey, I.D. Gilchrist, R.W. Jones, T. Troscianko, Visual search in Alzheimer's disease: a deficiency in processing conjunction of features, *Neuropsychologia* 40 (2002) 1849–1857.
- [28] J. Talairach, P. Tournoux, *A Co-planar Stereotaxic Atlas of the Human Brain*, Thieme, Stuttgart, 1988.
- [29] K.R. Thulborn, C. Martin, J.T. Voyvodic, Functional MR imaging using a visually guided saccade paradigm for comparing activation patterns in patients with probable Alzheimer's disease and in cognitively able elderly volunteers, *Am. J. Neuroradiol.* 21 (2000) 524–531.
- [30] A. Treisman, G. Gelade, A feature integration theory of attention, *Cogn. Psychol.* 12 (1980) 97–136.
- [31] A. Treisman, S. Sato, Conjunction search revisited, *J. Exp. Psychol.: Hum. Percept. Perform.* 16 (1990) 459–478.
- [32] D.T. Wilkinson, P.W. Halligan, R.N.A. Henson, R.J. Dolan, The effects of interdistraction similarity on search processes in superior parietal cortex, *NeuroImage* 15 (2002) 611–619.